Journal of Pediatric Surgery (2006) **41**, 1951–1956

ELSEVIER

Journal of Pediatric Surgery

www.elsevier.com/locate/jpedsurg

The second STEP: the feasibility of repeat serial transverse enteroplasty

Hannah Piper[a], Biren P. Modi[a], Heung Bae Kim[a], Dario Fauza[a], John Glickman[b], Tom Jaksic[a,*]

[a]*Department of Surgery, Children's Hospital Boston and the Harvard Center for Minimally Invasive Surgery, Harvard Medical School, Boston, MA 02115, USA*
[b]*Department of Pathology, Children's Hospital Boston and the Harvard Center for Minimally Invasive Surgery, Harvard Medical School, Boston, MA 02115, USA*

Index words:
STEP;
Serial transverse enteroplasty;
Bowel dilation;
Bowel lengthening;
Intestinal failure

Abstract

Background: Serial transverse enteroplasty (STEP) lengthens and tapers dilated bowel. Redilation of the STEP segment occurs in some patients with intestinal failure. The feasibility of a repeat STEP procedure in a pig model is evaluated.

Methods: Six pigs underwent reversal of an intestinal segment distal to the ligament of Treitz. At 6-week intervals after reversal, each animal had 2 STEP procedures on the bowel proximal to the reversed segment. Necropsy was performed up to 6 weeks after repeat STEP.

Results: Bowel length increased by 11.3 ± 3.9 cm and bowel diameter decreased from a mean of 5.3 ± 0.8 to 1.8 ± 0.4 cm ($P < .0001$) after the first STEP. After repeat STEP, bowel length increased by 16.7 ± 13.3 cm ($P < .01$), and the bowel was tapered from a mean of 5.4 ± 0.9 to 2.2 ± 0.4 cm ($P < .01$). Five pigs did well after repeat STEP, and 1 pig had early necropsy for bowel obstruction. None had histologic evidence of bowel ischemia in the repeat STEP segment.

Conclusions: A second STEP operation is feasible in a pig model and may be considered to optimize bowel length and function in select patients with intestinal failure.

In general, the small bowel has a significant reserve, and therefore, resection has minimal or no clinical nutritional consequences. However, the extent of resection that can be tolerated is variable for each patient. With that in mind, intestinal failure is defined not by the loss of a particular length of bowel, but as the inability to absorb adequate nutrients to maintain body weight or normal growth and development [1]. The surgical options available to ameliorate intestinal failure encompass procedures to restore bowel continuity, repair enteric fistulae, and resect strictured or dysmotile segments and operations to lengthen and taper the bowel [2].

The serial transverse enteroplasty (STEP) operation, initially described in an animal model in 2003 [3], is gaining acceptance as a beneficial procedure for select individuals with shortened and dilated residual small bowel. Patients with short bowel syndrome who are unable to wean completely from total parenteral nutrition (TPN) and patients with severe intestinal dysmotility with dilated bowel prone to bacterial overgrowth are examples of those

Presented at the 39th Annual Meeting of the Pacific Association of Pediatric Surgeons, May 14–18, 2006, Taipei, Taiwan.
* Corresponding author. Tel.: +1 617 355 8097; fax: +1 617 738 0864.
E-mail address: tom.jaksic@childrens.harvard.edu (T. Jaksic).

0022-3468/$ – see front matter © 2006 Elsevier Inc. All rights reserved.
doi:10.1016/j.jpedsurg.2006.08.015

who may be candidates for the STEP operation. The primary objectives of the operation are to both lengthen and taper the small bowel to improve overall absorption and motility. One advantage of the STEP operation is that the mesentery is minimally manipulated, and the potential for additional surgery remains.

To date, the short-term outcomes for children who have undergone the STEP operation are promising [4]. Most patients are able to tolerate a greater percentage of their caloric intake orally, and some are able to wean completely from TPN. Currently, the extent of intestinal adaptation after significant loss of length is not well established but may continue for several years in children [2]. After STEP, there is the potential for epithelial cell hyperplasia and luminal dilation. It is possible, therefore, that further gains in surface area and absorption could be made by repeating the STEP operation. The purpose of this study was to determine the feasibility of a repeat STEP operation in a large animal model.

1. Methods

All experimental protocols for this study were approved fully by the Harvard Medical School Animal Management Program. This program is sanctioned by the American Association for the Accreditation of Laboratory Animal Care (AAALAC, file 000009) and meets the National Institutes of Health standards for the care and use of laboratory animals.

1.1. Surgical creation of intestinal dilation

Young domestic female pigs (n = 6) were weighed on the morning of surgery and were then induced with a Telazol (6.6 mg/kg IM) and xylazine (2.2 mg/kg IM) mixture. Each animal was given 1 g of cefazolin intravenously and prepared with iodine-based solution. Anesthesia was maintained with inhaled isoflurane (2%-5%). The specific surgical procedure to create intestinal dilation has been previously described [5].

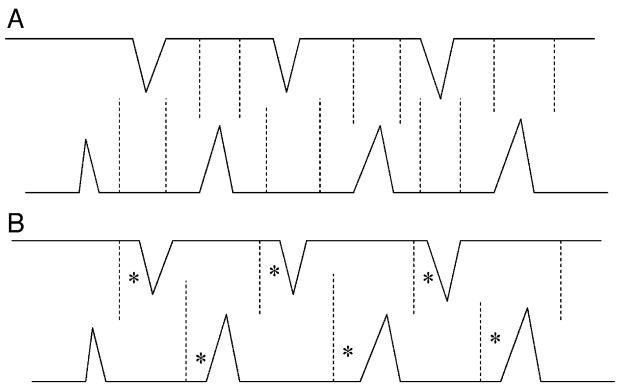

Fig. 1 There are 2 options for placing the staple lines during the repeat STEP operation when only minimal remodeling has occurred. Two additional staple lines may be placed between each initial line (A), or a single staple line may be placed between each initial line (B) resulting in several blind ends (*).

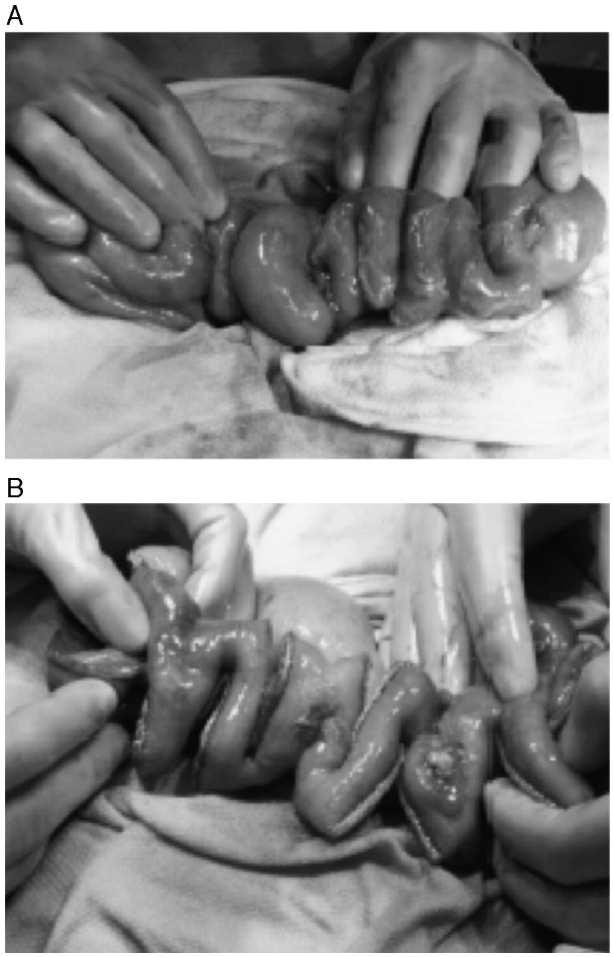

Fig. 2 The 2 methods of performing the repeat STEP are demonstrated in the animal model. A, Selective stapler firing preserves blood supply but results in occasional blind ends. B, Maximal length is gained when the stapler is applied on either side of the previous staple lines.

Briefly, a midline laparotomy incision was made and the small bowel exposed. A 60-cm segment of small bowel was measured starting approximately 130 cm distal to the ligament of Treitz. The 60-cm segment was then transected at both ends and rotated 180° to prepare for antiperistaltic anastomosis. Anastomoses were performed with a 4-0 polypropylene running suture in a single layer. The abdomen was then washed with 500 mL of warmed saline and closed in layers. Postoperatively, all animals had unrestricted access to water, and feeds with regular chow were given on postoperative day 1. A single dose of penicillin (750,000 U IM) was given on the morning of postoperative day 1. All animals were housed separately and were given equal amounts of pig chow daily.

1.2. Initial STEP

All animals were housed for 6 weeks after the initial reverse segment operation to allow for adequate small intestinal dilation. The pigs were then prepared for surgery

Table 1 Comparison of individual and mean animal characteristics

	Pig 1	Pig 2	Pig 3	Pig 4	Pig 5	Pig 6	Mean ± SD
Predilation weight (kg)	37.4	37.2	35.2	38.0	31.4	33.1	35.4 ± 2.7*
Pre-STEP weight (kg)	68.1	59.8	60.9	54.8	53.9	55.7	58.9 ± 5.3*
Pre-STEP 2 weight (kg)	80.9	85.9	85.2	84.1	60.5	82.2	79.8 ± 9.6*
Length gain from STEP (cm)	10	18	14	8	12	10	12.0 ± 3.6**
Length gain from repeat STEP (cm)	25	40	9	12	8	6	16.7 ± 13.3**
Interim growth (cm)	5	6	8	14	0	7	6.7 ± 4.5
Total length gain from STEP procedures (cm)	35	58	23	20	16	16	28.0 ± 16.3**
Maximum diameter pre-STEP (cm)	4.0	6.0	6.0	5.5	5.5	5.0	5.3 ± 0.8***
Maximum diameter post-STEP (cm)	1.5	2.0	2.0	2.0	2.0	1.0	1.8 ± 0.4***
Maximum diameter pre-STEP 2 (cm)	5.0	6.0	6.0	6.5	4.0	5.0	5.4 ± 0.9**
Maximum diameter post-STEP 2 (cm)	2.0	2.0	2.0	2.0	2.0	3.0	2.2 ± 0.4**

* $P < .03$.
** $P < .01$.
*** $P < .0001$.

as described previously. The same midline incision was used to reenter the abdomen. The dilated segment of bowel at least 4 cm in diameter and proximal to the reversed segment was identified and measured. A sterile marking pen was used to delineate the antimesenteric side of the small bowel. The STEP procedure was then performed as described previously [3]. Briefly, a 50-mm GIA stapler (US Surgical Corporation, Norwalk, Conn) was applied perpendicular to the long axis of the bowel and parallel to the mesenteric blood supply. The stapler was applied sequentially in this manner from opposite directions overlapping on alternating sides to create a "zigzag" channel. The number of stapler reloads applied varied somewhat among animals (range, 8-15) in an attempt to use 50 cm of bowel in each case. The length and diameter of the STEP segment were measured after all stapler applications were complete and a 3-0 Prolene suture was placed at both ends to mark the STEP segment for future identification. The abdomen was then washed with heparinized saline and closed in layers. Postoperative care was carried out as described previously, except that animals were given a liquid diet (Ensure) for the first 2 postoperative days.

1.3. Repeat STEP

The pigs were given a 6-week recovery period, during which time they were housed independently and given the same diet and caloric intake. The pigs were then prepared for surgery in the same manner as the previous 2 surgeries. The abdomen was reentered through the previous midline incision, and the STEP area of small bowel was isolated by identifying the staple lines and the marking sutures. The segment was measured in length and diameter. One of 2 techniques was applied to perform the repeat enteroplasty depending on the configuration of the STEP segment. If, on the one hand, the bowel segment had regained a near linear conformation, we reapplied the stapler in the same manner as in the initial STEP with little regard to the previous staple lines. If, on the other hand, the bowel had undergone minimal remodeling and the previous staple lines were more prominent, we either fired the stapler in the same position as previously or to either side of the prior staple line. The exact placement of new staple lines depended upon the bowel's blood supply to ensure that a mesenteric vessel was present between each pair of staple lines.

To test the limits of the operation and attempt maximal length gain, we applied the stapler twice between each of the old staple lines in an additional animal, pig 7. In other animals with minimal remodeling, we fired the stapler no more than once between the previous staple lines, creating a variable number of blind ends. The 2 approaches taken after minimal remodeling are seen in Figs. 1 and 2. An attempt

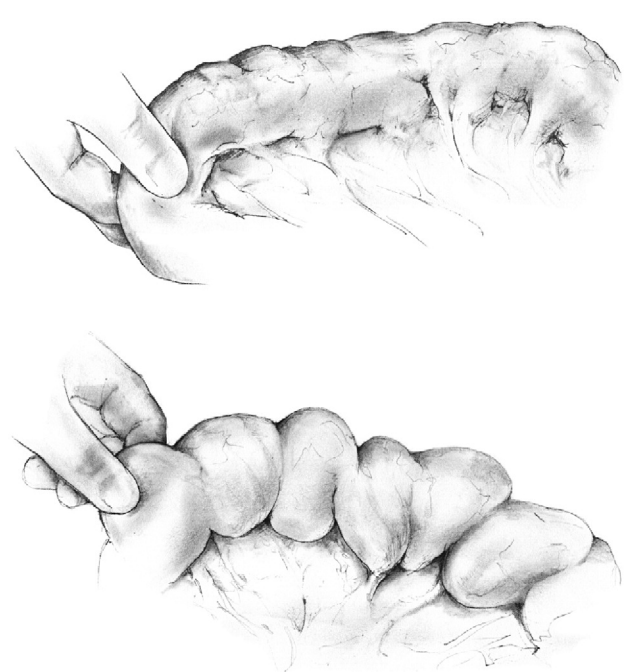

Fig. 3 Bowel remodeling in 2 of the animals resulted in a near linear configuration 6 weeks after the initial STEP operation.

was made to use the entire segment between marking stitches. Bowel length and diameter were measured after completion of the STEP procedure. In the cases where a blind end was created during the repeat STEP operation, it was not included in the total length of the bowel. The abdomen was then closed in layers, and the pigs were recovered as described above.

1.4. Postoperative analysis

The mean weight for all pigs and the mean length and diameter of the small bowel segments were compared at each point using analysis of variance with significance set at $P < .05$. All data were recorded as mean ± SD.

The animals were housed for up to 6 weeks after the repeat STEP operation at which time they underwent necropsy. If there was evidence that the animals were not recovering well from the surgery at any time, necropsy was performed earlier.

At the time of necropsy, the entire small bowel was examined for gross evidence of obstruction or ischemia. Representative samples of small bowel from the STEP segment as well as proximal and distal were harvested, flushed, and fixed in 10% formalin. Samples were then taken from each staple line, between each line, and proximal and distal to the STEP segment along the longitudinal axis in relation to the original bowel conformation. The samples were paraffin embedded, sectioned at 5 μm, and stained with both hematoxylin and eosin and trichrome stains.

2. Results

All 6 pigs survived the repeat STEP operation and continued to grow and gain weight throughout the study. The mean weight before each operation was 35.4 ± 2.7, 58.9 ± 5.3, and 79.8 ± 9.6 kg ($P < .01$). In addition, the animals gained significant small bowel length and underwent bowel tapering with each STEP procedure. Although there was variation in the total intestinal length gained, each animal had at least a combined 15-cm increase in small bowel length after both STEP operations (range, 16-58 cm). A summary of the quantitative analysis for each animal is seen in Table 1.

Fig. 4 In 4 of the animals, there was less remodeling, and some of the zigzag configuration from the initial operation remained at the time of repeat STEP.

Table 2 Animal outcomes

	Time to necropsy	Animal Status	Autopsy findings
Pig 1	6 wk	Healthy	No ischemia
Pig 2	6 wk	Healthy	No ischemia
Pig 3	2 wk	Bowel obstruction	Volvulus, no STEP ischemia
Pig 4	4 d	Neurologic disorder	No ischemia
Pig 5	6 wk	Healthy	No ischemia
Pig 6	6 wk	Healthy	No ischemia
Pig 7	7 d	Lethargic, weight loss	STEP ischemia

At the time of the repeat STEP operation, a range of bowel remodeling was seen. In all cases, there was interim dilation of the segments between the initial stapler applications as well as a partial loss of the original zigzag pattern. However, each animal's bowel configuration differed slightly. Pigs 1 and 2 were remodeled as seen in Fig. 3, and the other 4 had the pattern seen in Fig. 4. The additional animal, pig 7, also had visible staple lines from the initial STEP operation. This pig gained 14 cm of intestinal length with the first STEP operation, similar to the average for the other 6 pigs (12 cm). Six weeks later, at the time of the repeat STEP operation, we applied the stapler twice between each previous staple line, and pig 7 gained 61 cm of intestinal length. This was 3.5 times more than the average length gain (17 cm) for the other pigs during the repeat STEP.

Pigs 1 and 2 did not have any blind ends created from the repeat STEP secondary to the bowel's more linear configuration, whereas pigs 3 to 6 had an occasional blind end created during the repeat STEP (Fig. 1). By disregarding the mesenteric blood supply, we were able to avoid creating intestinal blind ends in pig 7; however, this animal survived for only 7 days after the repeat operation and, at the time of necropsy, was found to have evidence of ischemia in the STEP segment of bowel. The overall health of each animal and the small bowel status at the time of necropsy can be seen in Table 2. Although 2 other animals died prematurely, we did not find any evidence of ischemia in the STEP segments in either of these animals.

Upon reviewing the bowel histology at the time of necropsy, some significant findings were noted. The bowel proximal and distal to the STEP segment was essentially normal without distinction. In contrast, the segments having undergone 2 STEP procedures were found to have novel changes in each layer. Certain areas of the mucosa had evidence of decreased villus height with crypt cell regeneration, but otherwise appeared healthy. Extensive remodeling was noted in the muscularis propria including focal

interruption within the muscle fibers, and at times, it has no definitive orientation in terms of longitudinal vs circular patterns. Finally, in the subserosa and serosal layers, there was a degree of foreign body reaction near the staple lines ranging from giant cell infiltration to fibrosis depending on how long the animal had survived after repeat STEP.

3. Discussion

Current treatment of intestinal failure has improved significantly in recent years, including new strategies for both medical and surgical intervention [1,6]. Specifically, the STEP has become a surgical option not only for infants and children with small bowel syndrome, but also for older patients with severe bowel motility disorders and intestinal dilation. The STEP operation allows the surgeon to control the extent of both bowel lengthening and tapering. Because of this flexibility, the extent of intestinal remodeling after the STEP operation is variable. Because patients with intestinal failure live longer, longitudinal data are becoming available, and it appears that bowel adaptation including bowel dilation persists even after surgical intervention [3,7,8]. Therefore, a second STEP operation could prove to be an important option for certain patients.

One obvious benefit from a repeat STEP is the additional intestinal length. A recent study by Quiros-Tejeira et al [9] divided children into 3 groups based on the length of their small bowel and found that that infants with longer than 38 cm weaned from TPN more quickly and had better overall survival than those with less intestinal length. Infants with shorter than 15 cm of residual bowel had the highest mortality. Additional series have noted that infants with less than 20 to 30 cm are chronically dependent upon parenteral nutrition [2,10]. It therefore appears that the total length of small bowel matters most within a critical range and that a second STEP procedure after intestinal remodeling could be of significant benefit. Aggressive fluid and electrolyte management often allow patients to survive the acute phase of intestinal failure, and much of the morbidity and mortality is a result of long-term parenteral nutrition [2,11,12]. The sooner the patients are transitioned to enteral feeding, the less likely they are to succumb to complications.

A second STEP procedure is technically possible because the surgeon can choose the location of further stapler applications based on the bowel characteristics. Although applying the stapler multiple times in succession allows for maximal length gain, it is not always necessary or desirable. As we noted with the animal model, the degree to which the bowel regains a linear configuration and loses the zigzag pattern varies and cannot necessarily be predicted. When preparing for the second STEP, it is important to choose a segment of bowel that is sufficiently dilated ($\geq$4 cm) and insure that there is a mesenteric blood vessel between each staple line. The ideal scenario occurs when the bowel has regained a linear configuration before repeating the STEP operation. This allows the most significant gain in bowel length without any blind ends. We lengthened the bowel by 25 to 40 cm during the repeat STEP when this was the case compared with 6 to 12 cm when the bowel had only a partial linear configuration. It is possible that given adequate time postoperatively, all the animals would have regained a linear configuration.

The ability to preoperatively identify patients who have significantly remodeled the initial STEP segment could be useful and may be possible; however, it is not absolutely necessary. If a patient would benefit from additional bowel length or narrowing of a dilated segment after the first STEP operation, it may be worth repeating. If a blind end is created, it can be eliminated by simply stapling across it, which we did in 1 of our animals. This does not decrease the functional length of the small bowel but does reduce the risk of developing bacterial growth in this region. Whether an occasional diverticulum results in clinical sequelae requires further long-term investigation. This study was limited by the relatively short follow-up period and the fact that the animals did not have foreshortened bowel. However, despite the limitations, this model demonstrated the feasibility of repeating the STEP.

Intestinal failure continues to be a challenging clinical problem. Home parenteral nutrition and bowel rehabilitation programs have made it possible for patients to leave the hospital and participate in a wide variety of activities. However, there is room for further progress. These children too often suffer from repeated bloodstream infections and ultimately liver disease secondary to prolonged TPN use. Thus far, one of the most successful means of reducing morbidity and mortality from intestinal failure is to transition to enteral nutrition. Bowel lengthening surgery can facilitate this goal, and the STEP operation is a safe and effective option. This study provides preliminary evidence that STEP can be repeated on the same segment of bowel to taper and lengthen small bowel. Hopefully, this can be incorporated in the management of select patients as part of their intestinal rehabilitation.

References

[1] Sudan D, DiBaise J, Torres C, et al. A multidisciplinary approach to the treatment of intestinal failure. J Gastrointest Surg 2004;10:165-77.
[2] Vanderhoof JA, Young RF. Enteral and parenteral nutrition in the care of patients with short-bowel syndrome. Best Pract Res Clin Gastroenterol 2003;17:997-1015.
[3] Kim HB, Fauza D, Garza J, et al. Serial transverse enteroplasty (STEP): a novel bowel lengthening procedure. J Pediatr Surg 2003; 38:425-9.
[4] Javid PJ, Kim HB, Duggan C, et al. Serial transverse enteroplasty is associated with successful short-term outcomes in infants with short bowel syndrome. J Pediatr Surg 2005;40:1019-24.
[5] Chang RW, Javid PJ, Oh J, et al. Serial transverse enteroplasty enhances intestinal function in a model of short bowel syndrome. Ann Surg 2006;243:223-8.
[6] Scolapio J. Current update of short-bowel syndrome. Curr Opin Gastroenterol 2004;20:143-5.

[7] Bianchi A. Experience with longitudinal intestinal lengthening and tailoring. Eur J Pediatr Surg 1999;9:256-9.
[8] Keller J, Panter H, Layer P. Management of the short bowel syndrome after extensive small bowel resection. Best Pract Res Clinl Gastroenteroly 2004;18:977-92.
[9] Quiros-Tejeira RE, Ament ME, Reyen LR, et al. Long-term parenteral nutritional support and intestinal adaptation in children with short bowel syndrome: a 25-year experience. J Pediatr 2004;2:157-63.
[10] González HF, Pérez NB, Malpeli A, et al. Nutrition and immunological status in long-term follow up of children with short bowel syndrome. JPEN J Parenter Enteral Nutr 2004;29:186-91.
[11] Serrano MS, Schmidt-Sommerfeld E. Nutritional support of infants with short bowel syndrome. Nutrition 2002;18:966-70.
[12] Wales P, de Silva N, Kim JH, et al. Neonatal short bowel syndrome a cohort study. J Pediatr Surg 2004;40:755-62.